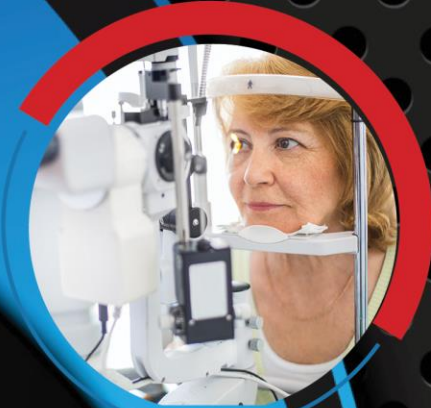

PRIMER

# SPOTLIGHT ON DIABETIC RETINOPATHY & DIABETIC MACULAR EDEMA



Facilitating **OPTIMAL OUTCOMES** for the Management of Retinal Diseases:  
*Health Plan Best Practice Recommendations*

Jointly provided by



This activity is supported by an independent medical education grant from Regeneron Pharmaceuticals, Inc.



# Diabetic Retinopathy (DR) and Diabetic Macular Edema (DME)

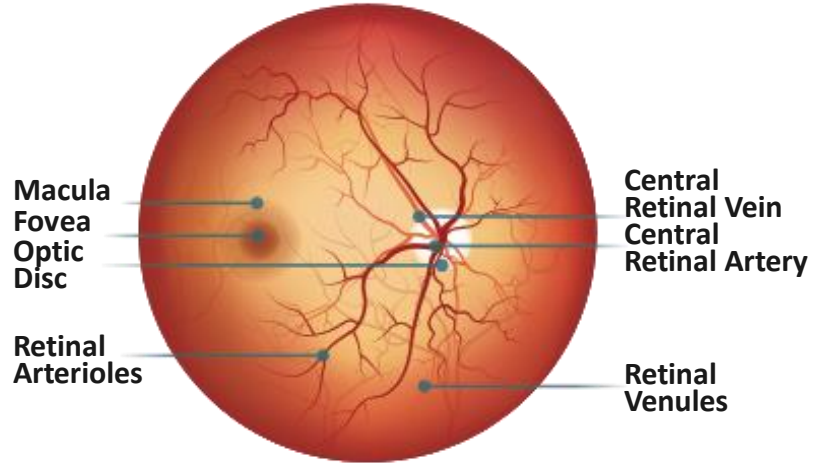
CLINICAL PRIMER FOR HEALTH CARE  
PAYERS AND PURCHASERS

# Disease Overview

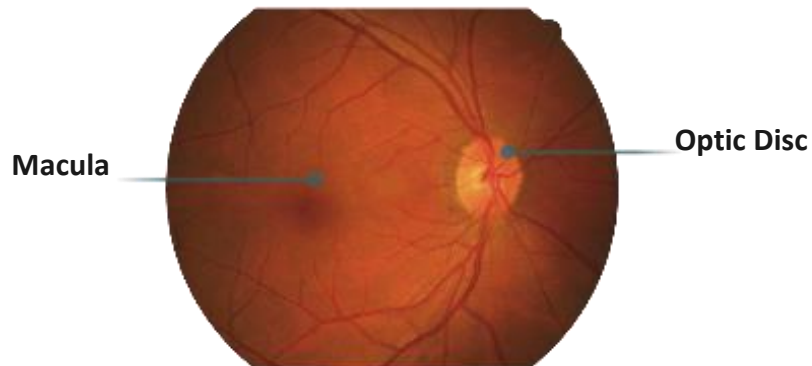
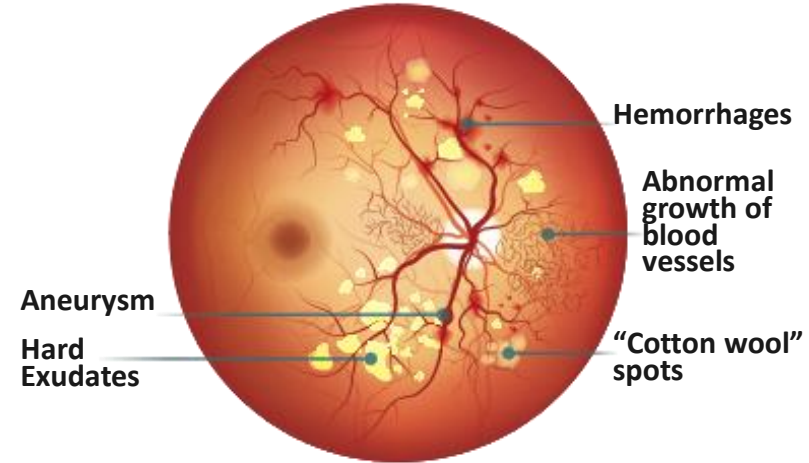
- Diabetic macular edema (DME) is the leading cause of legal blindness in persons with diabetes
- DME can be present at any stage of the disease but is more common in patients with proliferative diabetic retinopathy (DR)
- Duration of diabetes is a major risk factor associated with the development of diabetic retinopathy
- Due to the disproportionately large number of patients with type 2 diabetes, this group comprises a larger proportion of the disease burden in patients with visual impairment from DR
- The prevalence of DR and vision-threatening DR is expected to increase with increasing diabetes prevalence
- Only about 60% of people with diabetes have recommended yearly screenings for diabetic retinopathy

# Pathophysiology of the Progression of DR to DME

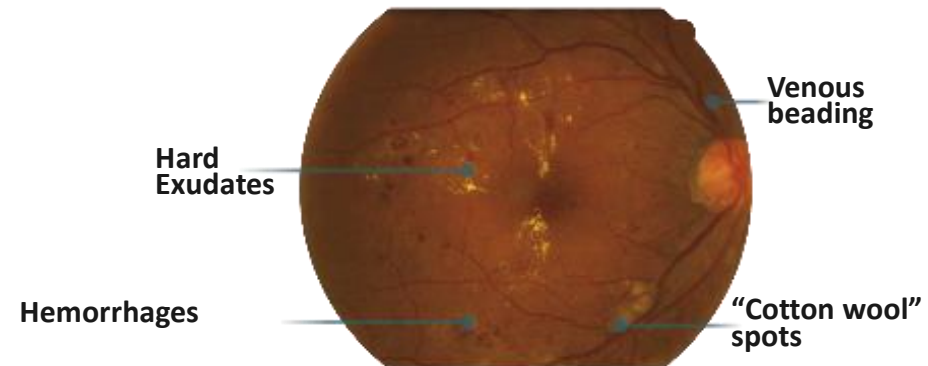
## Normal Retina



## Diabetic Retinopathy



Normal retina



Severe non-proliferative DR with severe DME

# Diagnosis

## History

- Duration of diabetes
- Past glycemic control (HbA1c)
- Medications
- Medical history (eg, obesity, renal disease, systemic hypertension, serum lipid levels, pregnancy, neuropathy)
- Ocular history (eg, trauma, other eye diseases, ocular injections, surgery, including retinal laser treatment and refractive surgery)

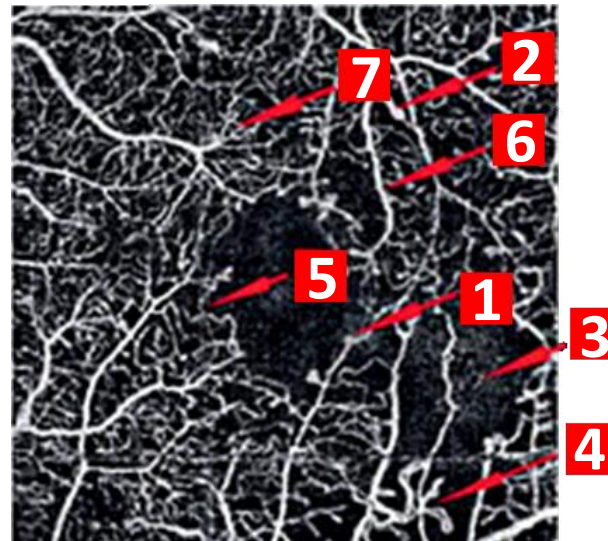
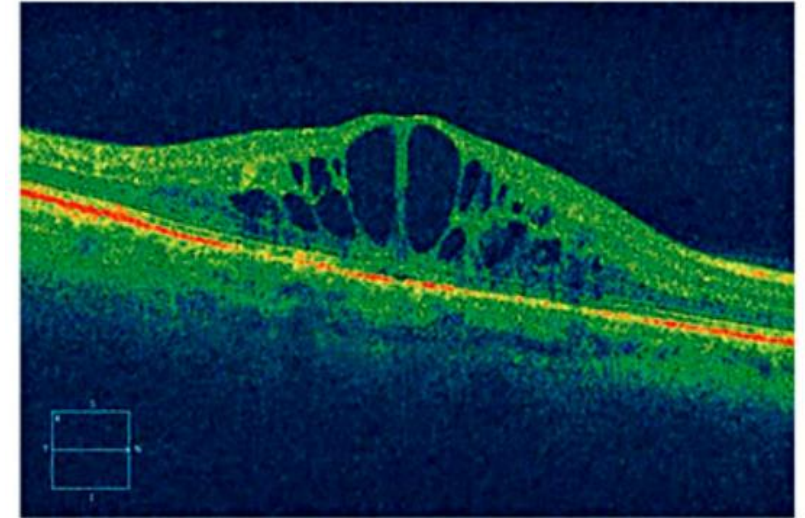
## Examination

- Visual acuity
- Slit-lamp biomicroscopy
- Intraocular pressure (IOP)
- Gonioscopy before dilation, when indicated
- Pupillary assessment for optic nerve dysfunction
- Thorough funduscopy, including stereoscopic examination of the posterior pole
- Examination of the peripheral retina and vitreous
- Assessment for the following features:
  - Macular edema
  - Signs of severe NPDR (extensive retinal hemorrhages/microaneurysms, venous beading, and IRMA)
  - Optic nerve head neovascularization and/or neovascularization elsewhere
  - Vitreous or preretinal hemorrhage



# Ancillary Tests

- Color and red-free fundus photography
- Optical coherence tomography (OCT)
- Fluorescein angiography (FA)
- OCT angiography
- B-scan ultrasonography



1. Microaneurysms
2. Vascular loops
3. Non-perfusion
4. Neovascularization
5. FAZ erosion
6. Venous beading
7. Multiple capillary beds

# DR Disease Severity Scale

Disease Severity Level	Findings Observable upon Dilated Ophthalmoscopy
No apparent retinopathy	No abnormalities
Mild NPDR	Microaneurysms only
Moderate NPDR	More than just microaneurysms but less than severe NPDR
Severe NPDR	
U.S. definition	Any of the following (4-2-1 rule) and no signs of proliferative retinopathy: <ul style="list-style-type: none"><li>• Severe intraretinal hemorrhages and microaneurysms in each of <b>4</b> quadrants</li><li>• Definite venous beading in <b>2</b> or more quadrants</li><li>• Moderate IRMA in <b>1</b> or more quadrants</li></ul>
International definition	Any of the following and no signs of proliferative retinopathy: <ul style="list-style-type: none"><li>• More than 20 intraretinal hemorrhages in each of <b>4</b> quadrants</li><li>• Definite venous beading in <b>2</b> or more quadrants</li><li>• Prominent IRMA in <b>1</b> or more quadrants</li></ul>
PDR	One or both of the following: <ul style="list-style-type: none"><li>• Neovascularization</li><li>• Vitreous/preretinal hemorrhage</li></ul>

IRMA = intraretinal microvascular abnormalities; NPDR = nonproliferative diabetic retinopathy; PDR = proliferative diabetic retinopathy

# Initial Treatment Recommendations for Patients with Diabetes

Severity of Retinopathy	Presence of Macular Edema	Follow-up (Months)	Panretinal Photocoagulation (Scatter) Laser	Focal and/or Grid Laser*	Intravitreal Anti-VEGF Therapy
Normal or minimal NPDR	No	12	No	No	No
Mild NPDR	No	12	No	No	No
	NCI-DME	3-6	No	Sometimes	No
	CI-DME <sup>†</sup>	1*	No	Rarely	Usually
Moderate NPDR	No	6-12 <sup>†</sup>	No	No	No
	NCI-DME	3-6	No	Sometimes	Rarely
	CI-DME <sup>†</sup>	1*	No	Rarely	Usually
Severe NPDR	No	3-4	Sometimes	No	Sometimes
	NCI-DME	2-4	Sometimes	Sometimes	Sometimes
	CI-DME <sup>†</sup>	1*	Sometimes	Rarely	Usually
Non-high-risk PDR	No	3-4	Sometimes	No	Sometimes
	NCI-DME	2-4	Sometimes	Sometimes	Sometimes
	CI-DME <sup>†</sup>	1*	Sometimes	Sometimes	Usually
High-risk PDR	No	2-4	Recommended	No	Sometimes
	NCI-DME	2-4	Recommended	Sometimes	Sometimes
	CI-DME <sup>†</sup>	1*	Recommended	Sometimes	Usually

Anti-VEGF = anti-vascular endothelial growth factor; CI-DME = center-involved diabetic macular edema; NCI-DME = noncenter-involved diabetic macular edema; NPDR = nonproliferative diabetic retinopathy; PDR = proliferative diabetic retinopathy

\*Adjunctive treatments that may be considered include intravitreal corticosteroids and anti-VEGF agents

†For patients with good visual acuity (20/25 or better) and CI-DME, there is no difference between observation plus aflibercept if visual acuity decreases, focal laser plus aflibercept if visual acuity decreases, or anti-VEGF therapy.

‡Or at shorter intervals if signs approaching those of severe NPDR appear.



# Best Practices in Clinical Management

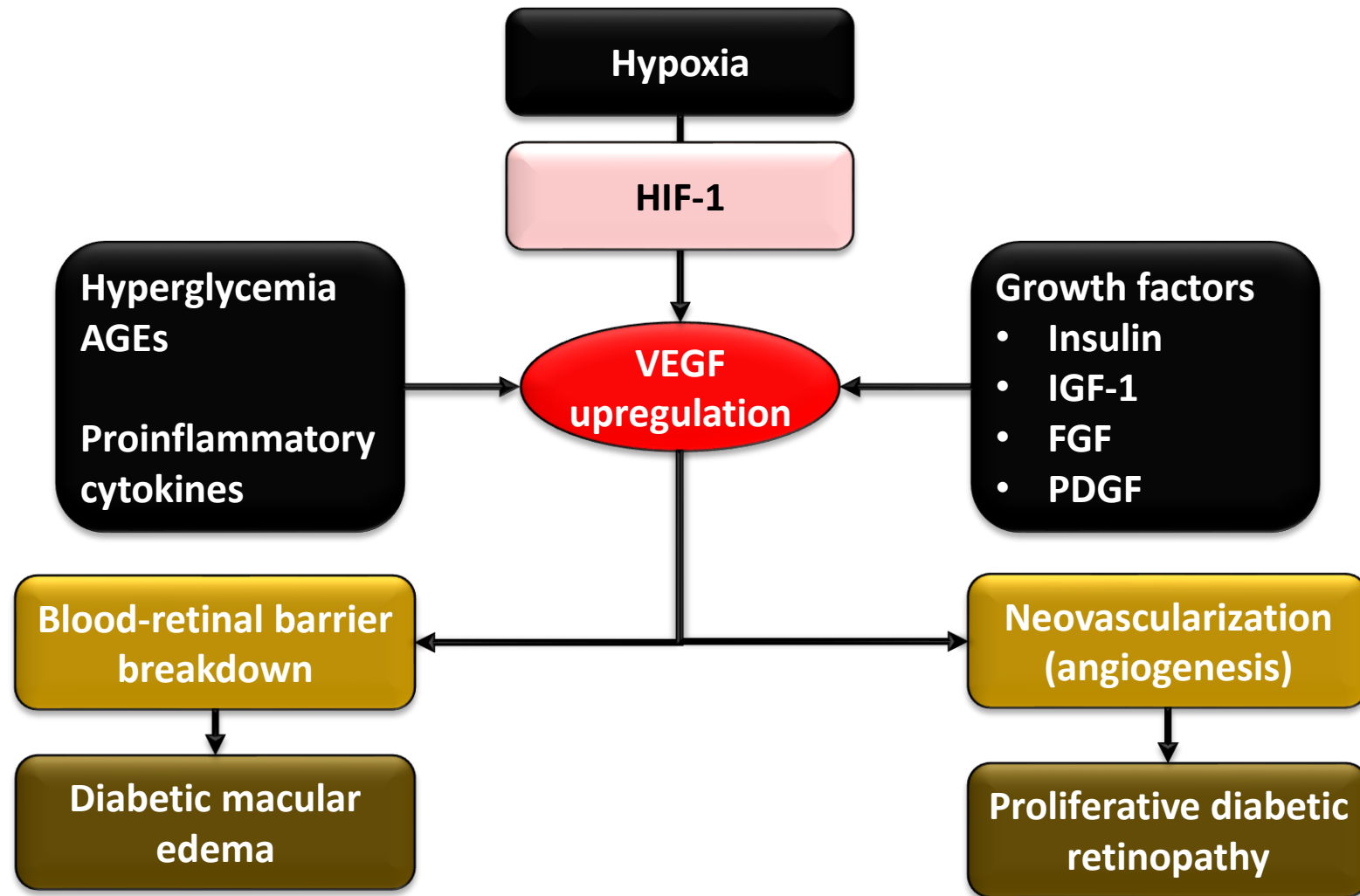
People with type 1 diabetes should have annual screenings for diabetic retinopathy beginning 5 years after the onset of their disease, whereas those with type 2 diabetes should have a prompt screening at the time of diagnosis and at least yearly screenings thereafter

Maintaining control of glucose and blood pressure lowers the risk of retinopathy developing and/or progressing, so patients should be informed of the importance of maintaining good levels of glycosylated hemoglobin, and blood pressure

***Intravitreal anti-vascular endothelial growth factor (anti-VEGF) agents are effective in the treatment of center-involved diabetic macular edema with vision loss***

- At this time, laser photocoagulation surgery remains the preferred treatment for non-center-involved diabetic macular edema and pan-retinal photocoagulation (PRP) surgery remains the mainstay treatment for proliferative diabetic retinopathy (PDR)

# The Role of VEGF in DR/DME




# Rationale for Anti-VEGF Treatment in DR/DME

Multiple, high-quality clinical trials have demonstrated that anti-VEGF therapy is more effective in improving vision in CI-DME than monotherapy with focal laser treatment, supplanting it as the first-line therapy

This was demonstrated with ranibizumab, bevacizumab, and aflibercept

- A significant portion of patients in these trials (30%-46%) underwent focal laser treatment. The timing of the laser—deferred or prompt—did not affect the outcome



With a monthly or a protocol-driven strategy such as DRCR.net studies with anti-VEGF, eyes with vision worse than 20/32 or worse due to CI-DME gained around 2 lines of vision at 2 years compared with stabilization of vision with focal treatment alone.

# Anti-VEGF Therapies for DR/DME

*FDA Indicated*

Aflibercept

Ranibizumab

Faricimab

Brolucizumab

*Off Label*

Bevacizumab

# FDA Approved Anti-VEGF Dosing Comparison for DR/DME

Anti-VEGF Therapy	Dosage Form	Dosing Schedule
<b>Aflibercept</b>	2 mg/0.05 mL solution 8 mg/0.07 mL solution	<ul style="list-style-type: none"> <li>2 mg (0.05 mL) administered by intravitreal injection every 4 weeks (monthly) for the first 5 injections followed by 2 mg (0.05 mL) via intravitreal injection once every 8 weeks (2 months)</li> <li>8 mg (0.07 mL) administered by intravitreal injection every 4 weeks (monthly) for the first 3 injections, followed by 8 mg (0.07 mL) every 8 to 16 weeks (2 to 4 months) in DME and every 8 to 12 weeks (2 to 3 months) for DR</li> </ul>
<b>Ranibizumab</b>	6 mg/mL solution (0.3 mg)	0.3 mg (0.05 mL) administered by intravitreal injection once a month (approximately 28 days)
<b>Brolucizumab</b>	6 mg/0.05 mL solution	6 mg (0.05 mL of 120 mg/mL solution) every 6 weeks (approximately every 39-45 days) for the first five doses, followed by one dose of 6 mg (0.05 mL of 120 mg/mL solution) every 8-12 weeks
<b>Faricimab</b>	120 mg/mL solution	<ol style="list-style-type: none"> <li>6 mg (0.05 mL of 120 mg/mL solution) administered by intravitreal injection every 4 weeks (approximately every 28 days ± 7 days, monthly) for at least 4 doses. If improvement after 4 doses, the interval of dosing may be modified by extensions of up to 4-week interval increments or reductions of up to 8-week interval increments.</li> <li>6 mg administered every 4 weeks for the first 6 doses, followed by 6-mg dose via intravitreal injection at intervals of every 8 weeks (2 months) over the next 28 weeks.</li> </ol>

EYLEA [package insert]. Tarrytown, NY: Regeneron Pharmaceuticals. Available at: [https://www.regeneron.com/downloads/eylea\\_fpi.pdf](https://www.regeneron.com/downloads/eylea_fpi.pdf). Revised June 2021. Accessed July 2022.

LUCENTIS [package insert]. South San Francisco, CA: Genentech. Available at: [https://www.gene.com/download/pdf/lucentis\\_prescribing.pdf](https://www.gene.com/download/pdf/lucentis_prescribing.pdf). Revised March 2018. Accessed July 2022

BEOVU [package insert]. East Hanover, NJ: Novartis. Available at: <https://www.novartis.us/sites/www.novartis.us/files/beovu.pdf>. Revised May 2022. Accessed July 2022

VABYSMO [package insert]. South San Francisco, CA: Genentech. Available at: [https://www.gene.com/download/pdf/vabysmo\\_prescribing.pdf](https://www.gene.com/download/pdf/vabysmo_prescribing.pdf). Revised January 2022. Accessed July 2022



# Potential Concerns with Compounded Bevacizumab



**Bevacizumab** is used off-label, and currently it must be repackaged in much smaller aliquots containing a small fraction of the dose used in cancer therapy



Ophthalmologists look to compounding pharmacies to create single-use vials of the appropriate dose



The process requires aseptic technique and compliance with USP General Chapter 797



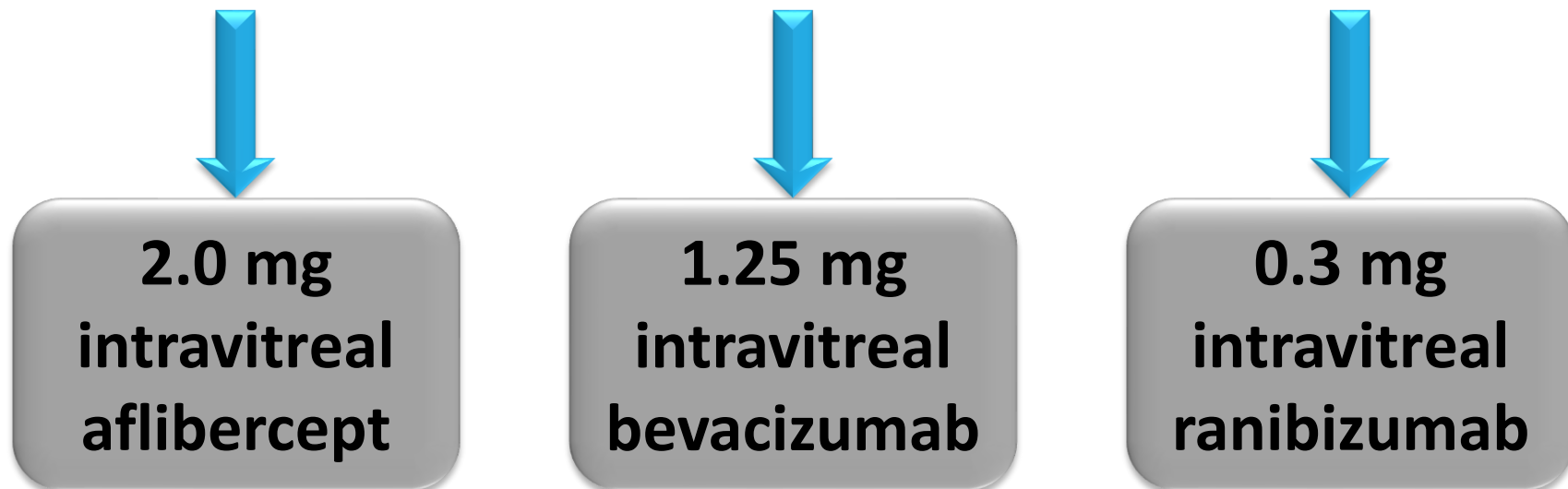
The **repackaging of bevacizumab** has given rise to concerns about impurities that could be introduced during the process, sterility, and dosage consistency

# Treatment Response in DR/DME Can Differ According to Anti-VEGF Therapy: The Protocol T Study

## DRCR.net Protocol T

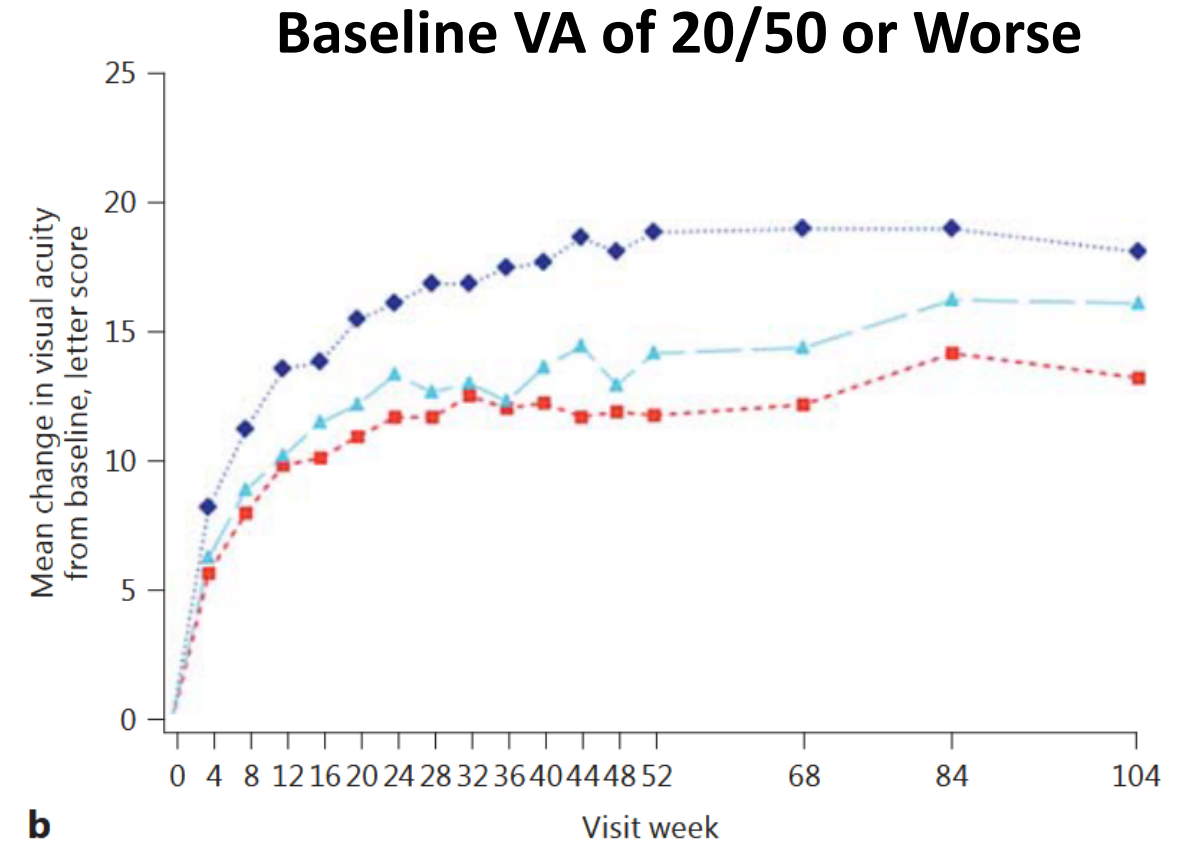
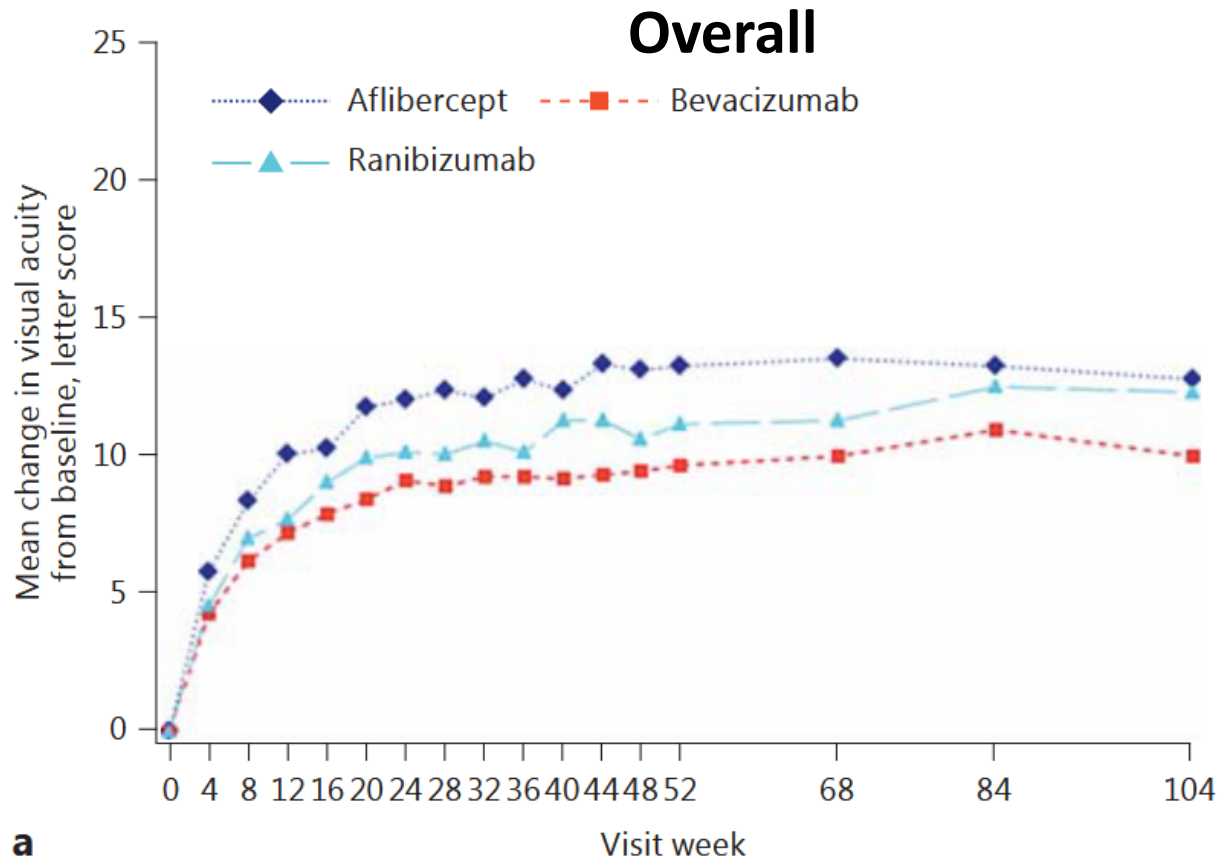
### Study Objective and Treatment Arms (N=660)

To compare the efficacy and safety of (1) intravitreal aflibercept, (2) intravitreal bevacizumab, and (3) intravitreal ranibizumab when given to treat central-involved DME in eyes with visual acuity of 20/32 to 20/320.



# Mean Change in Visual Acuity Over Time Stratified by Baseline Visual Acuity

## DRCR.net Protocol T

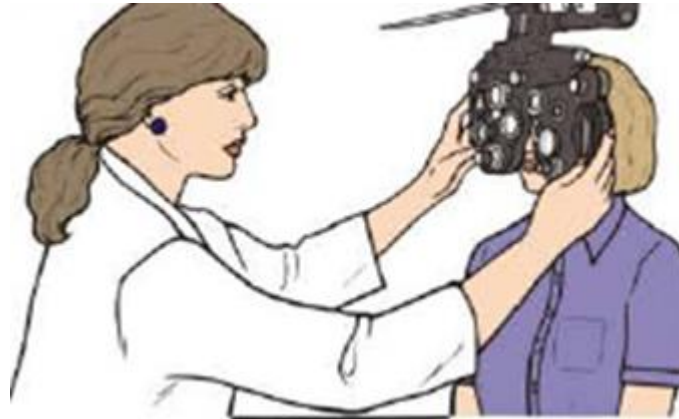

Out to 24 weeks, persistent DME was more likely with bevacizumab than with aflibercept or ranibizumab.  
Aflibercept=32%; Bevacizumab=66%; Ranibizumab=41% - **A vs. B**,  $P < 0.001$ ; **A vs. R**,  $P = 0.05$ ; **R vs. B**,  $P < 0.001$

# Change in Visual Acuity Outcomes at 2 Years Among Eyes With/Without Chronic Persistent DME

## DRCR.net Protocol T

Among eyes with persistent DME, eyes assigned to bevacizumab were more likely to have chronic persistent DME than eyes assigned to aflibercept ( $P=0.03$ ).



	Chronic Persistent DME through 2 y					
	Yes			No		
	Afl (N=29)	Bev (N=70)	Ran (N=38)	Afl (N=30)	Bev (N=31)	Ran (N=29)
Mean change in visual acuity from baseline*	14.8	10.3	9.3	10.2	10.7	14.7
≥10-letter gain	62%	51%	45%	63%	55%	66%
≥10-letter loss	0%	3%	3%	3%	3%	0%

\*With vs. without chronic persistent DME: Afl,  $P=0.05$ ; Bev,  $P=0.86$ ; Ran,  $P=0.04$

# A Recent Study Assessed Appropriate Sequencing of Anti-VEGF Therapies in DME

A total of 312 eyes (in 270 adults) underwent randomization

158 eyes were assigned to receive aflibercept monotherapy and 154 to receive bevacizumab first

Over the 2-year period, 70% of the eyes in the bevacizumab-first group were switched to aflibercept therapy due to suboptimal response

- The mean improvement in visual acuity was 15.0 letters in the aflibercept-monotherapy group and 14.0 letters in the bevacizumab-first group (adjusted difference, 0.8 letters; 95% confidence interval, -0.9 to 2.5;  $P=0.37$ )
- At 2 years, the mean changes in visual acuity and retinal central subfield thickness were similar in the two groups



# Considerations on Use of Biosimilars in Ophthalmic Practice

*“The successful and cost effective off-label use of bevacizumab for eye disease for over 15 years represents a unique history of a well-studied biologic agent injected into the eye, which has yet to be duplicated for bevacizumab biosimilars.”*

*“Before a biosimilar is required to be used for treatment or included in a step therapy regimen, it should be FDA-approved for the ophthalmic indication.”*



AMERICAN ACADEMY  
OF OPHTHALMOLOGY®

*“CMS has learned that some MA plans are using biosimilars to Avastin (i.e., Zirabev and Mvasi) as substitutes for Avastin to treat eye issues...”*

*“Unlike Avastin, the off-label use of these biosimilars in MA step therapy programs is not supported by widely used treatment guidelines or clinical literature. CMS remains concerned that off-label use of drugs without support from clinical research is potentially dangerous to MA enrollees and is prohibited by regulation.”*



# Coding Considerations

	ICD-9 CM	ICD-10 CM
Diabetic retinopathy:		
Background	362.01	<ul style="list-style-type: none"><li>• E10.311 Type 1 with macular edema</li><li>• E10.319 Type 1 without macular edema</li><li>• E11.311 Type 2 with macular edema</li><li>• E11.319 Type 2 without macular edema</li><li>• E13.311 other specified types of diabetes mellitus with unspecified diabetic retinopathy with macular edema</li><li>• E13.319 other specified types of diabetes mellitus with unspecified diabetic retinopathy without macular edema</li></ul>
Proliferative	362.02	<ul style="list-style-type: none"><li>• E10.351 Type 1 with macular edema</li><li>• E10.359 Type 1 without macular edema</li><li>• E11.351 Type 2 with macular edema</li><li>• E11.359 Type 2 without macular edema</li><li>• E13.351 other specified diabetes mellitus with proliferative diabetic retinopathy with macular edema</li><li>• E13.359 other specified diabetes mellitus with proliferative diabetic retinopathy without macular edema</li></ul>

# Coding Considerations (cont.)

	ICD-9 CM	ICD-10 CM
Nonproliferative, NOS	362.03	<ul style="list-style-type: none"> <li>• E10.321 Type 1 with macular edema</li> <li>• E10.329 Type 1 without macular edema</li> <li>• E11.321 Type 2 with macular edema</li> <li>• E11.329 Type 2 without macular edema</li> <li>• E13.321 other specified types of diabetes mellitus with mild nonproliferative diabetic retinopathy with macular edema</li> <li>• E13.329 other specified types of diabetes mellitus with mild nonproliferative diabetic retinopathy without macular edema</li> </ul>
Nonproliferative, mild	362.04	
Nonproliferative, moderate	362.05	<ul style="list-style-type: none"> <li>• E10.331 Type 1 with macular edema</li> <li>• E10.339 Type 1 without macular edema</li> <li>• E11.331 Type 2 with macular edema</li> <li>• E11.339 Type 2 without macular edema</li> <li>• E13.331 other specified types of diabetes mellitus with moderate nonproliferative diabetic retinopathy with macular edema</li> <li>• E13.339 other specified types of diabetes mellitus with moderate nonproliferative diabetic retinopathy without macular edema</li> </ul>

# Coding Considerations (cont.)

	ICD-9 CM	ICD-10 CM
Diabetic retinopathy (continued):		
Nonproliferative, severe	362.06	<ul style="list-style-type: none"> <li>• E10.341 Type 1 with macular edema</li> <li>• E10.349 Type 1 without macular edema</li> <li>• E11.341 Type 2 with macular edema</li> <li>• E11.349 Type 2 without macular edema</li> <li>• E13.341 other specified types of diabetes mellitus with severe nonproliferative diabetic retinopathy with macular edema</li> <li>• E13.349 other specified types of diabetes mellitus with severe nonproliferative diabetic retinopathy without macular edema</li> </ul>
Diabetic macular edema	362.07	<ul style="list-style-type: none"> <li>• E10.321 Type 1 mild nonproliferative diabetic retinopathy</li> <li>• E10.331 Type 1 moderate nonproliferative diabetic retinopathy</li> <li>• E10.341 Type 1 severe nonproliferative diabetic retinopathy</li> <li>• E10.351 Type 1 proliferative diabetic retinopathy</li> <li>• E11.321 Type 2 mild nonproliferative diabetic retinopathy</li> <li>• E11.331 Type 2 moderate nonproliferative diabetic retinopathy</li> <li>• E11.341 Type 2 severe nonproliferative diabetic retinopathy</li> <li>• E11.351 Type 2 proliferative diabetic retinopathy</li> <li>• E13.321 other specified diabetes mellitus with mild nonproliferative diabetic retinopathy</li> <li>• E13.331 other specified diabetes mellitus with moderate nonproliferative diabetic retinopathy</li> </ul>

ICD = International Classification of Diseases; CM = Clinical Modification used in the United States; NOS = not otherwise specified

Additional information:

- Certain ICD-10 CM categories have applicable 6<sup>th</sup> characters. In the diabetic retinopathy series, indicate "with or without" macular edema. Laterality indicators are not required in this series.
  - 1 = with macular edema
  - 9 = without macular edema
- For bilateral sites, the final character of the codes in the ICD-10 CM indicates laterality. If no bilateral code is provided and the condition is bilateral, separate codes for both the left and right side should be assigned. Unspecified codes should be used only when there is no other code option available.